

Case Report

Phantom Erectile Penis after Sex Reassignment Surgery

Yuzaburo Namba*, Narushi Sugiyama, Shuji Yamashita, Eijiro Tokuyama,
Kenjiro Hasegawa, and Yoshihiro Kimata

*Department of Plastic and Reconstructive Surgery, Okayama University Graduate School of Medicine,
Dentistry and Pharmaceutical Sciences, Okayama 700-8558, Japan*

Between January 2001 and December 2007, we performed vaginoplasty as sex reassignment surgery in a total of 14 male-to-female transsexual (MTFTS) patients [1]. Several complications occurred such as partial flap necrosis, rectovaginal fistula formation and hypersensitivity of the neoclitoris. Just after the operation, some patients feel that their penises still exist, but by several weeks postoperatively, this sensation has disappeared. Herein we report a case of MTFTS in whom the sensation of a phantom erectile penis persisted for much longer.

Key words: gender identity disorder, sex reassignment surgery, phantom erectile penis

The phenomenon of the phantom limb occurs frequently after the amputation of the upper or lower extremities. The mechanism of the phantom sensation has now been analyzed, and treatments for phantom limb pains have been developed. Mirror-image training is a representative treatment approach. On the other hand, reports on the phantom penis and its treatment are very rare. We experienced a patient who underwent sex reassignment surgery in whom the sensation of a phantom erectile penis persisted.

Case Report

A 52-year-old man who was diagnosed as having MTFTS underwent penectomy, castration and vaginoplasty (Figs. 1, 2). He complained postoperatively of hypersensitivity of the neoclitoris and the sensation of a phantom erectile penis. The hypersensitivity of the neoclitoris was reduced within 3 months, but the feeling of a phantom erectile penis continued for over 6

months and was enhanced when the patient was standing. We performed a second operation to reduce the erectile tissue. We scooped out the external urinary meatus and incised the penile flap in a reverse T shape (Fig. 3). The bulbocavernosus muscle was exposed (Fig. 4), after the excision of which, (Fig. 5), the corpus spongiosum penis was exposed. We excised this as much as possible, but were careful not to create any urethral stenosis (Fig. 6). After suturing the tunica albuginea corpus spongiosum (Fig. 7), we closed the wound (Fig. 8). The phantom sensation disappeared just after the second operation. The urinary catheter was removed 3 weeks after the second operation, and there was no disturbance of the patient's urination.

Discussion

Weir Mitchell first reported the "phantom limb" phenomenon in 1871 [2], and the "phantom penis" was reported by Crone in 1951 [3]. It is believed now that "cross-activation" between the de-afferented cortex and the surrounding areas is the cause of the phantom phenomenon. Ramachandran introduced mir-

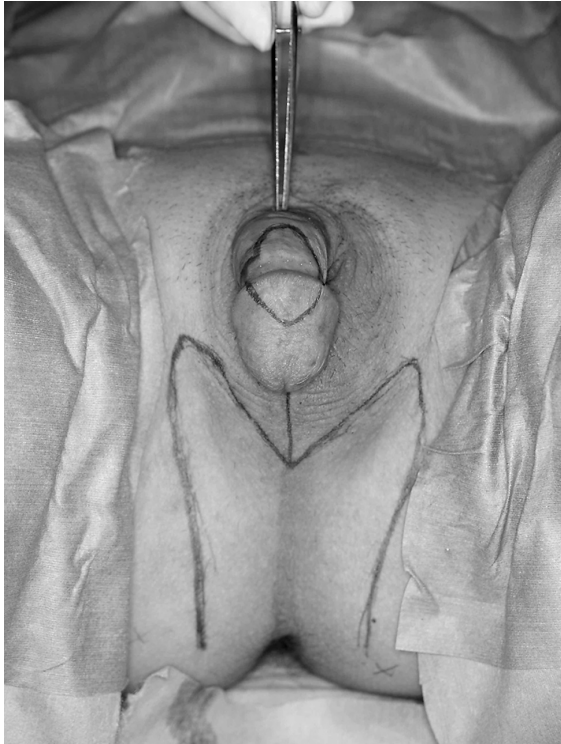


Fig. 1 Design of sex reassignment surgery.

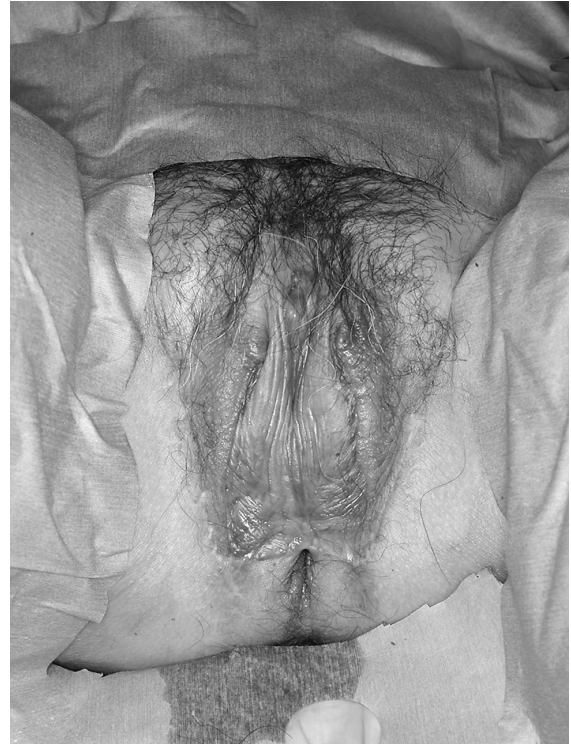

Fig. 2 Six months after the first operation.

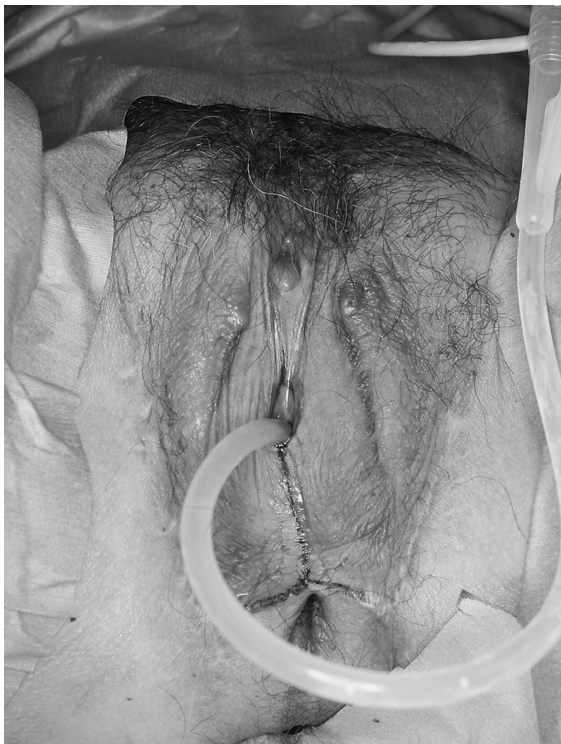

Fig. 3 Design of the second operation.

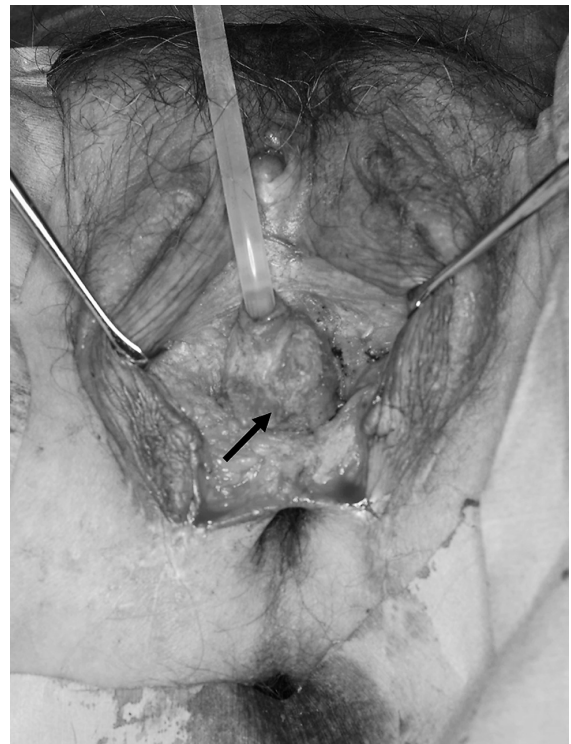


Fig. 4 Exposure of the bulbocavernosus muscle.

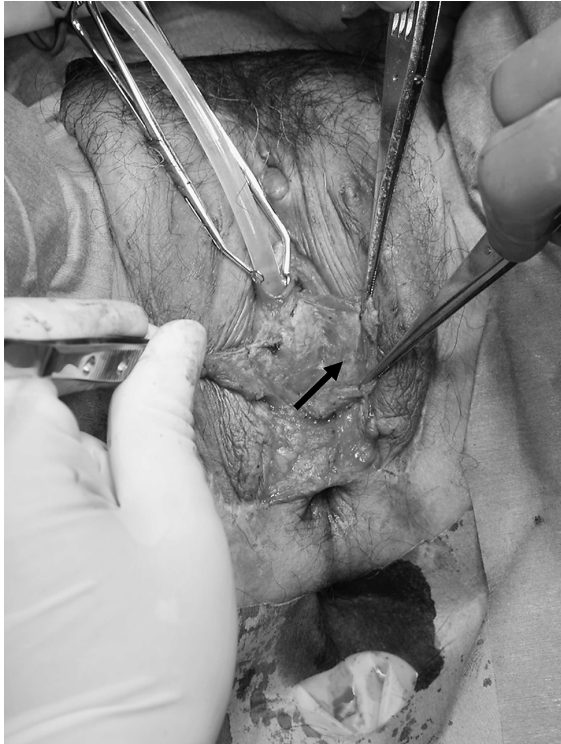

Fig. 5 Excision of the bulbocavernosus muscle.

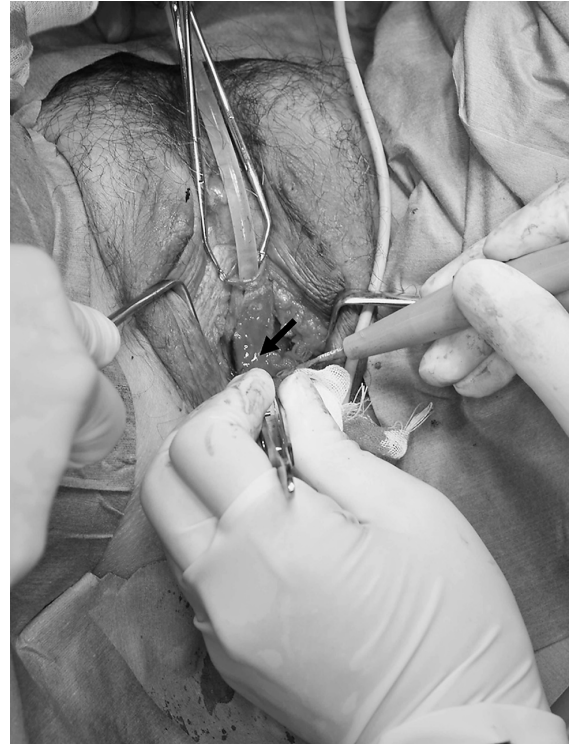

Fig. 6 Excision of the bulbar corpus spongiosum penis.

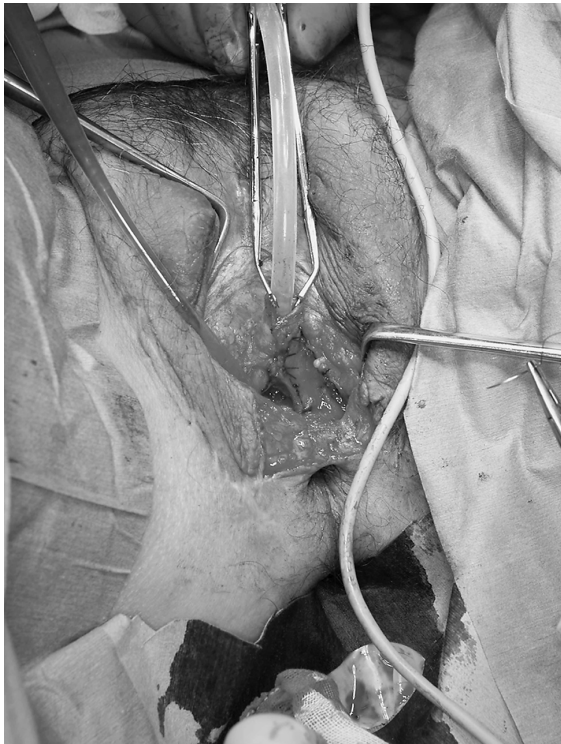

Fig. 7 Suturing the tunica albuginea corpus spongiosum.

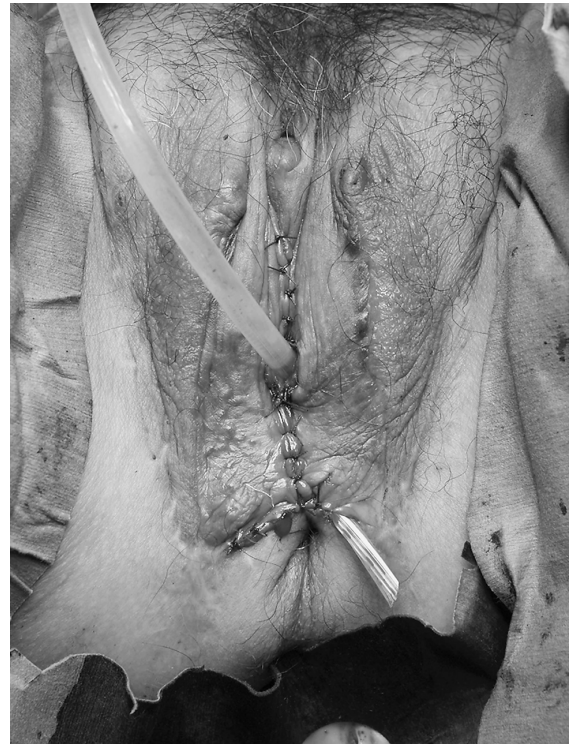


Fig. 8 Just after the second operation.

ror-image training to reorganize the brain map as a treatment for the phantom limb phenomenon [4]. He also predicted that MTFTS patients would be much less likely to experience a phantom penis than a “normal” man who had had his penis amputated for another reason [5]. We experienced an MTFTS case, however, who complained of a persistent phantom erectile penis for some months postoperatively. In his case, we left the bulbocavernosus muscle and bulbar corpus spongiosum penis intact during the first operation, and, in addition to the phantom erectile penis, he also complained that they tended to swell up. We therefore planned to reduce the erectile tissue, and after the second operation, the phantom sensation disappeared. Based on our experience with this one patient, the continued existence of the bulbocavernosus muscle and

bulbar corpus spongiosum penis postoperatively might be the cause of the phantom erectile penis.

References

1. Namba Y, Sugiyama N, Yamashita S, Hasegawa K, Kimata Y, Ishii K and Nasu Y: Vaginoplasty with an M-Shaped Perineo-Scrotal Flap in a Male-to -Female Transsexual. *Acta Med Okayama* (2007) 61: 355-360.
2. Mitchell SW: Phantom limbs. *Lippincott's Mag* (1871) 8: 563-569.
3. Crone-Munzebrock A: Phantom sensation after amputation of the penis. *Z Urol* (1951) 41: 819-822.
4. Ramachandran VS and Rogers-Ramachandran D: Synaesthesia in phantom limbs induced with mirrors. *Proc Biol Sci* (1996) 263: 377-386.
5. Ramachandran VS and Mcgeoch PD: Occurrence of phantom genitalia after gender Reassignment surgery. *Med Hypotheses* (2007) 69: 1001-1003.